

ΑΝΑΣΚΟΠΗΣΗ REVIEW

Θρομβωτική θρομβοπενική πορφύρα-μια όχι συχνή εκδήλωση των ρευματικών παθήσεων.

Λάζαρος Ι. Σακκάς, MD, DM, PhD(UK), FRCP(UK), Ευαγγελία Γεωργίου, MD

Ρευματολογική Κλινική, Πανεπιστημιακό Γενικό Νοσοκομείο Λάρισας και Ιατρική Σχολή, Πανεπιστήμιο Θεσσαλίας

ΠΕΡΙΛΗΨΗ

Η θρομβωτική θρομβοπενική πορφύρα (ΘΘΠ) ανήκει με μια ομάδα συνδρόμων, με το όνομα θρομβωτική μικροαγγειοπάθεια (ΘΜΑ). Η ΘΜΑ προκαλείται από εκτεταμένη θρόμβωση και ενδοθηλιακή βλάβη μικρών αγγείων (μικροαγγειοπάθεια) που οδηγεί σε μικροαγγειοπαθητική αιμολυτική αναιμία (ΜΑΑΑ), θρομβοπενία εκ κατανάλωσης, και ισχαιμική βλάβη οργάνων. Η ΘΘΠ οφείλεται σε έλλειψη του ADAMTS13, μια πρωτεάση που διασπά πολυμερή του παράγοντα von Willebrand. Η έλλειψη του ADAMTS13 μπορεί να είναι κληρονομική ή επίκτητη. Η κληρονομική ΘΘΠ οφείλεται σε μετάλλαξη του γονιδίου ADAMTS13. Η επίκτητη ΘΘΠ οφείλεται σε αντι-ADAMTS13 ανασταλτικά αυτοαντισώματα. Η τελευταία είναι ιδιοπαθής ή δευτεροπαθής σε συστηματικό ερυθρηματώδη λύκο. Η ΜΑΑΑ είναι αιμολυτική αναιμία (αύξηση LDH, αύξηση έμμεσης χολερυθρίνης) που είναι μη αυτοάνοση (άμεση Coombs αντίδραση, αρνητική), και ενδοαγγειακή (σχιστοκύτταρα στο πλακάκι αίματος, χαμηλή αιμοσφαιρίνη ορού). Η θρομβοπενία στη ΘΘΠ είναι βαρεία με αριθμό αιμοπεταλίων <30.000/uL. Το όργανο που προσβάλλεται πιο συχνά είναι το κεντρικό νευρικό σύστημα, ενώ η νεφρική προσβολή δεν είναι πολύ συχνή και συνήθως ήπια. Η κύρια θεραπεία είναι η πλασμαφαίρεση που είναι πολύ αποτελεσματική αλλά πρέπει να αρχίσει όσο το δυνατό πιο έγκαιρα για να έχει καλή αποτελεσματικότητα. Επιπρόσθετη ανοσοκαταστολή με στεροειδή, rituximab, cyclophosphamide και άλλα χρειάζονται για την πρόληψη υποτροπών.

Υπεύθυνος αλληλογραφίας:

Καθηγητής Λάζαρος Ι. Σακκάς
Ρευματολογική Κλινική, Ιατρικό Τμήμα,
Σχολή Επιστημών Υγείας,
Πανεπιστήμιο Θεσσαλίας
Βιόπολις 41110, Λάρισα
Τηλ +241350 2813, Fax: +2413501016,
E-mail: lsakkas@med.uth.gr

Corresponding author:

Professor Lazaros I. Sakkas
Department of Rheumatology
Faculty of Medicine,
School of Health Sciences,
University of Thessaly and University
General Hospital of Larissa
Biopolis 41110, Larissa
Tel:+241350 2813, Fax:+241350 1016,
E-mail: lsakkas@med.uth.gr

Mediterr J Rheumatol 2015; 26(2): 12-17

Λέξεις-Κλειδιά: θρομβοπενία, θρομβωτική θρομβοπενική πορφύρα, θρομβωτική μικροαγγειοπάθεια, συστηματικός ερυθρηματώδης λύκος

Thrombotic thrombopenic purpura-an unusual manifestation of rheumatic diseases.

Lazaros I. Sakkas, MD, DM, PhD(UK), FRCP(UK) , Eva Georgiou, MD

Department of Rheumatology, Faculty of Medicine, School of Health Sciences, University of Thessaly, Larissa, Greece

ABSTRACT

Thrombotic thrombopenic purpura (TTP) belongs to a group of syndromes, known as thrombotic microangiopathy (TMA). Thrombotic microangiopathy is caused by thrombosis and injury of endothelial cells in small vessels (microangiopathy) that results in microangiopathic haemolytic anaemia (MAHA), consumptive thrombocytopenia, and organ injury. Thrombotic thrombopenic purpura is caused by deficiency of ADAMTS13 (A Disintegrin And Metalloproteinase with Thrombospondin Type 1 motif, member 13) that cleaves von Willebrand factor polymers. ADAMTS13 deficiency may be hereditary or acquired. Hereditary ADAMTS13 deficiency is caused by mutation of the relevant gene. Acquired ADAMTS13 deficiency is caused by anti-ADAMTS13 inhibitory autoantibodies. The latter is idiopathic or secondary to systemic lupus erythematosus. Microangiopathic haemolytic anaemia is haemolytic anaemia (elevated serum LDH and indirect bilirubin) which is not autoimmune (direct Coombs test negative) and intravascular (schistocytes in peripheral blood smear, low-to-absent haptoglobin). Thrombocytopenia in TTP is severe with very low <math><30,000/uL</math> platelet count. The organ most frequently affected is central nervous system whereas renal injury is not frequent. The mainstay of treatment is plasma exchange which is very effective but must start as soon as possible for optimal effectiveness. Additional immunosuppressants to prevent relapses include steroids, rituximab, cyclophosphamide and others.

Mediterr J Rheumatol 2015; 26(2): 12-17

Keywords: Systemic lupus erythematosus, thrombocytopenia, thrombotic thrombopenic purpura, thrombotic microangiopathy

INTRODUCTION

Rheumatic diseases can affect other organs/systems besides connective tissues. Some manifestations due to hematologic involvement of central nervous system involvement can be the presenting manifestation of rheumatic diseases, and require early recognition and prompt treatment to achieve a successful outcome. In this report, we review thrombotic thrombopenic purpura (TTP).

THROMBOTIC THROMBOPENIC PURPURA

Thrombotic thrombopenic purpura (TTP) belongs to a group of syndromes, known as thrombotic microangiopathy (TMA). Thrombotic microangiopathy is characterized by thrombosis and endothelial damage in small vessels (arterioles and capillaries) that results in thrombocytopenia (due to platelet consumption), microangiopathic haemolytic anaemia (MAHA), and organ injury (due to ischemia). The most important clue for diagnosis of TMA is the diagnosis of MAHA. Microangiopathic haemolytic anaemia is haemolytic anaemia (elevated serum LDH and indirect bilirubin) which is non-immune (direct Coombs test negative) and intravascular (schistocytes in peripheral blood smear, and low-absent haptoglobin). The diagnostic algorithm in a patient with anaemia plus thrombocytopenia is shown in Table 1. Thrombotic microangiopathy encompasses several entities of different aetiologies (Table 2). Thrombotic thrombopenic purpura is caused by deficiency of ADAMTS13 (A Disintegrin And Metalloproteinase with Thrombopondin type 1 motif, member 13); a proteinase that is secreted from vascular endothelial cells and cleaves von Willebrand factor poly-

mers. Deficiency of ADAMTS13 results in very long von Willebrand factor polymers that clot small vessels. ADAMTS13 is hereditary or acquired.

Hereditary TTP is caused by homozygous or compound heterozygous mutations of ADAMTS13 gene. It occurs in children but also in pregnant women; as pregnancy is a trigger factor for TTP.

Acquired TTP is caused by anti-ADAMTS13 inhibitory autoantibodies, usually in patients with systemic lupus erythematosus. Acquired TTP can also be idiopathic. Acquired TTP is most frequent in adults but an infrequent entity with an incidence ranging from 0.2-1 cases/10⁵/year to 2.9 cases/million/year.^{1,2} It manifests with MAHA and thrombocytopenia. Platelet count frequently is very low (< 30,000/uL), hence purpura as a clinical sign. The central nervous system (CNS) is the most frequent organ affected usually with transient focal neurological manifestations, whereas kidneys are infrequently affected.

Diagnosis and differential diagnosis of TTP

Diagnosis of TTP is based on MAHA with very low platelet count, normal or mildly elevated serum creatinine, ADAMTS13 activity < 5-10%, or anti-ADAMTS13 antibodies (even in the presence of normal ADAMTS13 activity).³ Thrombotic thrombopenic purpura should be differentially diagnosed from other TMA syndromes (Table 2). Some of these syndromes are detailed below.

Shiga toxin-mediated TMA (Haemolytic uraemic syndrome)

Haemolytic uraemic syndrome (HUS) is caused by Shi-

Table 1. Algorithm of anaemia plus thrombocytopenia

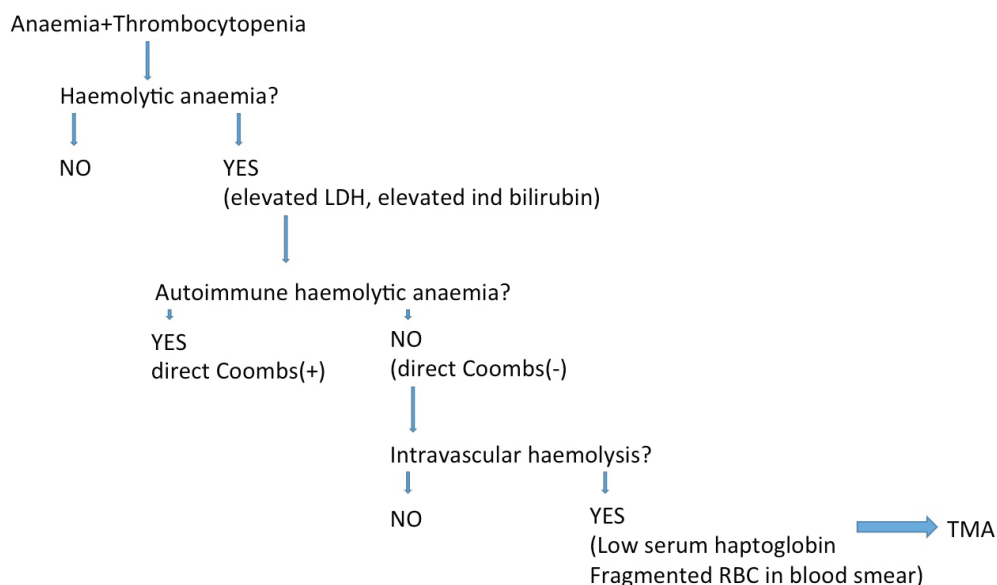


Table 2. Thrombotic microangiopathy syndromes

Thrombotic thrombopenic purpura (TTP)

ADAMTS13 deficiency

Hereditary (mutations of ADAMTS13 gene)

Acquired (anti-ADAMTS13 inhibitory antibodies)

Shiga toxin-mediated TMA (Haemolytic uraemic syndrome, HUS)

Shiga toxin-producing E.Coli (STEC)

Complement-mediated TMA (atypical HUS).

Mutation of complement factor H (CFH), CFI, membrane co-factor protein (MCP), C3 leading to uncontrolled activation of alternative pathway of complement

Malignancy-mediated TMA

Transplantation-mediated TMA

Pregnancy-associated TMA

TTP acquired or hereditary

HELLP

Pre-eclampsia

Drug-mediated TMA

Quinine, clopidogrel, cyclosporine, sirolimus, interferon, gemcitabine

Malignant hypertension-mediated TMA

Catastrophic antiphospholipid (CAPS)-mediated TMA

Infection (except STEC)-mediated TMA

ga toxin-producing Escherichia Coli. The most important E. Coli serotypes are O157:H7 and O104:H4.⁴ In these cases, mostly from uncooked burger, most often occur in children but also in women and the elderly. Haemolytic uraemic syndrome is preceded by bloody diarrhoea that can progress to bowel gangrene and perforation. The most frequently affected organ are the kidneys, followed by bowel, lung, pancreas and CNS. Diagnosis in a patient with MAHA, elevated serum creatinine and preceding diarrhoea is confirmed by the detection of Shiga toxin in stools and/or polymerase chain reaction (PCR) for Shiga toxin or Shiga toxin-producing E.Coli (STEC) in stools. Treatment is supportive with fluid repletion.

Complement-mediated TMA (Atypical HUS)

Complement-mediated TMA (atypical HUS) is caused by uncontrolled activation of the alternative pathway of complement. It is hereditary, caused by loss-of-function mutation of inhibitory complement factors (complement factor H [CFH], complement factor I [CFI], membrane cofactor protein [MCP] which inhibits C3 convertase), or gain-of-function mutation of C3.⁵ It can

also be acquired, caused by anti-complement factor H inhibitory antibodies.

Atypical HUS is suspected in a patient with MAHA, thrombocytopenia plus elevated serum creatinine, without preceding diarrhoea. Shiga toxin in stools is negative and ADAMTS13 activity is normal. Diagnosis is confirmed by analysis of gene mutations of CFH, CFI, MCP, and C3. Serum levels of C3, CFH, and CFI are usually decreased but they may be normal.

Drug-mediated TMA

Drugs can cause TMA either due to immune-mediated process or to toxicity. Immune-mediated TMA manifests with acute onset of symptoms within 21 days, following the exposure to a medication. In this category, quinine is most frequently reported. Toxic drug-mediated TMA is due to toxic dose or manifests with gradual onset, often presenting as renal failure. In this category, cyclosporine, tacrolimus, sirolimus, interferon, gemcitabine, and bevacizumab are included.⁶

Scleroderma renal crisis

Scleroderma renal crisis (SRC) occurs in 4-6% of pa-

tients with systemic sclerosis (SSc), predominantly in the diffuse cutaneous SSc during the first 4 years of the disease. It manifests with hypertension, elevated serum creatinine, and TMA, with moderate decrease in platelet count.⁷

HELLP syndrome

Features of Hemolysis, Elevated Liver enzymes, Low Platelet count (HELLP) syndrome include severe hypertension, heavy proteinuria, ADAMTS13 activity normal, diffuse intravascular coagulation, and no fever.

Other causes of TMA, mentioned in Table 2, such as malignancy and malignant hypertension, should be searched for. Other unusual causes to be considered follow.

Vitamin B12 metabolism abnormality

Abnormalities of cobalamin C (vitamin B12) can cause TMA. These abnormalities are caused by homozygous or compound heterozygous mutation of a gene for methylmalonic aciduria and homocystinuria type C protein that results in hyperhomocysteinemia, decreased plasma methionine and methylmalonic aciduria. It occurs in infants and very rarely in adults with MAHA, thrombocytopenia, and elevated serum creatinine.⁸ Distinguished features for vitamin B12 deficiency include leukopenia with hypersegmented neutrophils in peripheral blood, and megaloblasts and giant myeloid precursors in bone marrow aspirate.⁹ Diagnosis is confirmed by hyperhomocysteinemia, decreased plasma methionine, and methylmalonic aciduria.

Paroxysmal nocturnal hemoglobinuria (PNH)

Paroxysmal nocturnal hemoglobinuria carries an increased risk of thrombosis and can manifest with MAHA and thrombocytopenia. Paroxysmal nocturnal hemoglobinuria is a clonal disorder affecting multiple haematopoietic lineages and is caused by a deficiency of complement regulatory proteins CD55 and CD59. Paroxysmal nocturnal hemoglobinuria, as causing chronic intravascular haemolysis, leads to iron deficiency and iron repletion can exacerbate haemolysis. Diagnosis is confirmed by cytometric-based test for CD55 and CD59 in peripheral blood.⁹

Thrombotic microangiopathy should also be differentiated from diffuse intravascular coagulation (DIC).

In DIC, tissue factor released from injured endothelia and monocytes activates factor VII to initiate thrombosis, thus leading to depletion of FV, FX, and fibrinogen. As a consumptive syndrome, DIC manifests with low platelet count, prolonged PT, prolonged APTT, low fibrinogen, elevated D-dimers. There is also decreased protein C, and decreased antithrombin III.¹⁰

Treatment of TTP

In acquired TTP, plasma exchange (PE) plus corticosteroids are the standard treatment and should start as soon as possible. PE (40-60 mL/Kg) daily for 5 days or until platelet count >150,000/uL and serum LDH normal for two consecutive days, and stable or improved neurological status, according to 2012 American Association of Apheresis Consensus statement.¹¹ About 40% of primary TTP relapse or are refractory to PE and require additional immunosuppression.¹² Additional medications to prevent relapses include rituximab, cyclophosphamide or other immunosuppressants.

In a new patient with MAHA and thrombocytopenia, we start with PE. If ADAMTS13 activity is not low (<10%), and there is elevated creatinine, we start with Eculizumab until complement genetic studies are available.¹³

REFERENCES

1. Rosove MH. Thrombotic microangiopathies, *Semin Arthritis Rheum* 2014; 43: 797-805.
2. Reese JA, Muthurajah DS, Kremer Horinga JA, Vesely SK, Terrell DR, George JN. Children and adults with thrombotic thrombopenic purpura associated with severe acquired Adamts13 deficiency: comparison of incidence, demographic and clinical factors. *Pediatr Blood Cancer* 2013; 60: 1676-82.
3. George JN. Measuring ADAMTS13 activity in patients with suspected thrombotic thrombocytopenic purpura: when, how, and why? *Transfusion* 2015; 55: 11-3.
4. Jandhyala DM, Vanguri V, Boll EJ, Lai Y, McCormick BA, Leong JM. Shiga toxin-producing *Escherichia coli* O104:H4: an emerging pathogen with enhanced virulence. *Infect Dis Clin North Am* 2013; 27: 631-49.
5. Davin J-C, van de Kar NC. Advances and challenges in the management of complement-mediated thrombotic microangiopathies. *Ther Adv Hematol* 2015; 6: 171-85.
6. Al-Nouri ZL, Reese JA, Terrell DR, Vesely SK, George JN. Drug-induced thrombotic microangiopathy: a systematic review of published reports. *Blood* 2015; 25: 616-8.
7. Mouthon L, Bussone G, Berezné A, Noël LH, Guillevin L. Scleroderma renal crisis. *J Rheumatol* 2014; 41: 1040-8.
8. George JN, Nester CM. Syndromes of thrombotic microangiopathy. *N Engl J Med* 2014; 371: 654-66.
9. Green R. Anemias beyond B12 and iron deficiency: the buzz about other B's, elementary, and nonelementary problems. *Hematology Am Soc Hematol Educ Program* 2012; 2012: 492-8.
10. Nguyen TC, Carcillo JA. Bench-to-bedside review: thrombocytopenia-associated multiple organ failure--a newly appreciated syndrome in the critically ill. *Crit Care* 2006; 0: 235-43.
11. Sarode R, Bandarenko N, Brecher ME, Kiss JE, Marques MB, Szczepiorkowski ZM, et al. Thrombotic thrombocytopenic purpura: 2012 American Society for Apheresis (ASFA) consensus conference on classification, diagnosis, management, and future research. *J Clin Apher* 2014; 29: 148-67.
12. Clark WF. Thrombotic microangiopathy: current knowledge and outcomes with plasma exchange. *Semin Dial* 2012; 25: 214-9.
13. Scully M, Goodship T. How I treat thrombotic thrombocytopenic purpura and atypical haemolytic uraemic syndrome. *Br J Haematol* 2014; 164: 759-66.